

CASE REPORT: HEMICHOREA-HEMIBALLISMUS IN NON-KETOTIC HYPERGLYCEMIA AND NON-HEMORRHAGIC STROKE PATIENT WITH BASAL GANGLIA HYPERDENSITY

Regina Caecilia Setiawan¹, Luh Kadek Trisna Lestari², William Septian Sonyo²

¹Bangli Medika Canti Hospital, Bangli, Bali, Indonesia

²Department of Neurology, Bangli General Regional Hospital, Bangli, Bali, Indonesia

Diterima 22 Februari 2019

Disetujui 29 April 2019

Publikasi 27 Mei 2019

Korespondensi: reginacaecilia@yahoo.com

Cara merujuk artikel ini: Setiawan (et al). 2019. *Case Report: Hemichorea-Hemiballismus in Non-Ketotic Hyperglycemia and Non-hemorrhagic stroke patient with basal ganglia hyperdensity*. Callosum Neurology Journal 2(2): 72-77. DOI: <https://doi.org/10.29342/cnj.v2i2.78>

ABSTRACT

Background: Hemichorea-hemiballismus (HC-HB) is a hyperkinetic disorder of uncontrolled movements mostly in the proximal extremity on one side of the body. The most common cause is acute cerebrovascular disorder. The second is Non-ketotic hyperglycemia. This case is rare and the prevalence is unknown.

Case: A 60-year-old female came with involuntary, repetitive, and non rhythmic movements in the left arm and leg. She had a history of uncontrolled type 2 diabetes mellitus and hypertension. Head CT-scan showed hyperdense lesions in the right basal ganglia and infarction in the right temporal lobe. Symptoms improved after blood glucose had been controlled by basal and prandial insulin.

Discussion: HC-HB is often caused by lesions in basal ganglia and contralateral subthalamic nucleus. Clinical manifestations of the patient supports non-ketotic hyperglycemia and basal ganglia hyperdensity.

Conclusion: The prognosis of HC-HB is good in most patients with or without treatment. This case report describes a successful treatment approach with positive results in fairly short duration.

Keywords: hemichorea, hemiballismus, hyperglycemia, basal ganglia hyperdensity

Background

The most common etiology of hemichorea-hemiballismus (HC-HB) is acute cerebrovascular disorder,^{1,2} followed by non-ketotic hyperglycemia.² However, this case is quite rare.^{3,4} Diabetes mellitus (DM) is an endocrine disorder that most often occurs in Indonesia. Stroke and neuropathy is some of the most common long term complications of DM, especially in uncontrolled DM. Complications on neurovascular system can involve the brain, spinal cord, cranial nerves, autonomic nervous system, or peripheral nervous system.³ However, HC-HB is not the same as other neurological complications, because its complexity, so it becomes a challenge for doctors to be diagnosed as one of the complications of diabetes. If there is a part of the structure of the brain neurons involved, the patient can present with symptoms of choreiform and HC-HB is one of the choreiform type that can be a manifestation of hyperglycemia due to uncontrolled DM.^{4,5} The following cases are rare and the prevalence is still unknown.

Case Report

A 60-year-old female is admitted to hospital with symptoms of arms and legs moving involuntarily since 15 days ago. Movement occurs on the left side of upper and lower limb, especially in the proximal part. Movement that appears like jerking, hitting and dancing roughly. The first movement appears right after she woke up and the movement cannot be controlled by the patient. Abnormal movements improve when the patient sleeps, but when she woke up the movement reappears. The patient has just been diagnosed with diabetes mellitus 2 weeks before and have not taken anti diabetic medications. Patients also have a history of hypertension for 1 year but did not take medication as well. On the physical examination, the patient was fully alert with Glasgow Coma Scale (GCS) E4V5M6. Blood pressure was 140/90 mmHg, heart rate was 84x/minute regular, respiratory rate was 18x/minutes, temperature 36.7°C. Cranial nerve examination is normal and no pathological reflex is found in the patient. Involuntary movement was observed in examination. It was not rhythmical, fast, repetitive and continues like jerking and

dancing roughly on the left side of the upper and lower of proximal extremities.

Laboratory tests were performed on patients, blood glucose was 622 mg/dl, fasting blood glucose 270 mg/dl, urea 57 mg/dl, serum creatinine 0.53mg/dl. Blood examination showed leukocytosis (12,100/mm³). There was mild hyponatremia(132.5mmol/L),hypochloremia(86.7mmol/L). The potassium and calcium level (4.25mmol/L and 2.22mmol/L) were within normal range. Complete urine result is also within normal limit and there is no ketonuria. Lipid profile was normal. Non-contrast brain computed tomography (CT) was performed in patients and there was hyperdensity in right basal ganglia and ongoing infarction in right temporal lobe (Figure 1).

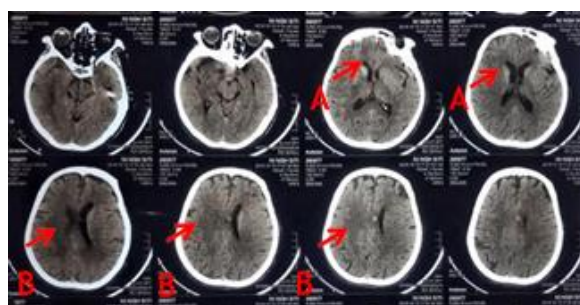


Figure 1. Non-contrast computed tomography scan of the patient showed (A, arrow) hyperdensity of the right basal ganglia and (B, arrow) ongoing infarction in the right temporal lobe.

Based on clinical symptoms and patient history, the cause of hemiballismus in this patient is suspected to be related to the history of uncontrolled type 2 diabetes mellitus. Then the patient was hospitalized. Blood glucose control, symptomatic and supportive therapy was given. We also monitored for other accompanying symptoms. The patient was given citicolin intravenous 2x500 mg, Aspirin 1x80 mg PO, clobazam 2x10 mg PO, haloperidol 2x1.5 mg PO. Insulin therapy was also given to this patient, with basal insulin dose of 14 IU and 3x6 IU of rapid acting insulin. The patient's blood glucose was monitored every day. Patients were treated for 10 days at Bangli General Hospital and discharged after the conditions are stabilized and the blood glucose is normal. After 3 months of follow-up, with regular control once every month, the patient's involuntary movement showed very significant improvement. The involuntary movement was resolved completely.

Discussion

Hemichorea-hemiballismus (HC-HB) is one of the most common types of choreiform involuntary movements.^{3,4} HC-HB is a hyperkinetic disorder which is characterized by movements that are uncontrolled, non-rhythmical, and often occur in the proximal limb, in one side of the body. HC-HB occurs due to interference on the contralateral basal ganglia, especially in the striatum area. HC-HB is mainly caused by the presence of systemic processes, both focal and diffuse.^{6,7} Focal processes include infections of the central nervous system such as encephalitis, toxoplasmosis, vasculitis, stroke, cysts, neoplasms, tuberculomas, any vascular malformations, neurodegenerative disorders, and demyelinating plaques.^{6,7} Diffuse systemic processes can include non-ketotic hyperglycemia, hyperparathyroidism, autoimmune disorders such as Lupus, Wilsons disease, and thyrotoxicosis.⁵ Other causes of HC-HB can be due to the use of drugs such as levodopa, phenytoin and oral contraception.⁴ Hemiballismus can be classified as primary or acquired.⁴ Hyperglycemia or hypoglycemia, hypernatremia and hyponatremia, hypomagnesemia, and hypocalcemia can be the metabolic causes of acquired hemiballismus. However, these cases are rare.⁸

Diabetes mellitus is a disease that disrupts glucose metabolism which can lead to conditions of hyperglycemia and this chronic disease is associated with chronic inflammation and can cause various systemic complications. HC-HB can be manifested as an initial symptom or complication of DM. HC-HB is the main symptom in this case. Non-ketotic hyperglycemia can occur with a variety of neurological symptoms including hyperosmolar coma, seizures, and hemichorea-hemiballismus (HC-HB).⁴ In this patient, it can be observed that patient's control of her glucose levels is poor and as a result of a very high and chronically increase in serum blood glucose level, blood hyperviscosity happened, which eventually causes ischemia in the basal ganglia and causes a decrease in the production of gamma-butyric acid (GABA) and acetylcholine at basal ganglia.^{2,9} This causes disruption of impulse transmission. The dopaminergic activity increased very high due to loss of inhibitor factors, resulting in continuous and

irregular jerking of the limbs. This patient also has on going acute ischemic stroke, so the cause of HC-HB in this patient is more likely combination between metabolic cause which is type 2 diabetes mellitus and the ischemic stroke.

Non-ketotic hyperglycemia is known to be a metabolic cause of HC-HB, especially in elderly

patients with uncontrolled diabetes mellitus. The underlying pathophysiology is not fully understood. Different mechanisms have been hypothesized. Acute putamen dysfunction, protein dissociation or denaturation after the occurrence of the wallerian degeneration is one of the most trusted mechanisms behind imaging findings. Petechial bleeding, microcalcifications, edema, reactive astrocytes, and interneuronal responses have been studied as a possible hypothesis.² Several other mechanisms have also been suggested to explain the pathophysiology of the occurrence of this syndrome, including acute infarction, microhemorrhagic in basal ganglia, or injury secondary to hyperviscosity and vasogenic edema. Hypoperfusion of cerebral blood flow to the basal ganglia, GABA and acetylcholine depletion, metabolic acidosis, many deposition products of myelin breakdown, deposits of calcium and other minerals are other hypothesized etiologies.¹⁰ The most accepted theory of HC-HB is hypoperfusion due to blood hyperviscosity caused by the condition of hyperglycemia which increases anaerobic metabolism by reducing GABA levels.^{2,11} MRI is an examination that is recommended to assess changes in the putamen and caudate nucleus.^{2,4} The presence of T1 hyperintensity is the most common finding. In peripheral areas that does not have MRI, CT-scan can be done. In CT scan, hyperdensity of basal ganglia and subtle hyperdensity in the striatal area can also be found. The pathophysiological mechanism underlying the findings on imaging is controversial. These typical findings on imaging are thought to be the result of hemorrhagic processes. But according to the neuropathology study by Ohara et al, in this finding there is only found astrocytosis without hemosiderin deposits. So it is hypothesized that the imaging findings result from progressive pathological reactions during infarction process and

it means that these findings are more related to the presence of blood vessel disorders than petechial bleeding or hyperglycemia.¹²

Vascular and structural lesions in the contralateral subthalamic nucleus and basal ganglia are the most common causes of HC-HB. Non-hemorrhagic and hemorrhagic stroke are the most common etiologies. Although stroke is the most frequent etiology of HC-HB, the incidence of HC-HB as a clinical manifestation compared to other manifestations that occur in stroke is very low. Arboix et al. reported that of 2,500 stroke patients, only 2 patients had HC-HB as clinical manifestations.¹³ Transient HC-HB associated with non-ketotic hyperglycemia is another very important etiology because it is the second most common cause of HC-HB.¹⁴ This syndrome is characterized by the onset of chorea / ballismus during hyperglycemic episodes. Blood glucose ranges from 500 - 1000 mg/dL during crisis of hyperglycemic. Movement that arises is usually unilateral, but can arise generalized in rare cases. Clinical manifestations of movement can vary from mild chorea to severe ballismus. In a review of 53 cases, Oh et al. showed that the average age of onset was 71, with female dominance 1.8: 1.15 Genetic factors play a role with Asian dominance in reported cases.^{15,16} Characteristic findings on MRI and CT-scan for basal ganglia hyperdensity seen in almost all cases.

Management of the patient can be achieved by normalizing blood glucose levels, although lesions on imaging can take up to 6 months to show improvement.¹⁷ In refractory and severe cases, haloperidol, risperidone, topiramate, and benzodiazepines can be used, especially with any atypical antipsychotics.⁴ In general, the prognosis is very good if it can be identified and given management as early as possible. In this case, the HC-HB symptom that occurs is typically associated with a condition of non-ketotic hyperglycemia in type 2 diabetes mellitus. Management of patient gradually by controlling the state of hyperglycemia.

HC-HB can improve over time and often no specific treatment is needed. Determining etiology is the most important in the management of HC-HB, such as optimal blood sugar management,

overcoming existing structural lesions or infection.¹⁴ Patients with HC-HB secondary to acute stroke require evaluation and management of stroke therapy. In patients with HC-HB due to non ketotic hyperglycemia, the main therapy is controlling blood glucose, along with long-term control of diabetes.¹⁵ Management of pharmacology has a role in preventing injury when severe ballismus movements occur, and treating patients with chronic HC-HB. Based on several studies, levodopa often worsens the symptoms of chorea. Early treatment with dopamine receptor blocking agents (chlorpromazine or haloperidol) in patients with HC-HB is declared successful.¹ General management of HC-HB often accompanied by neuroleptic drugs (haloperidol, metachlopramide, olanzapine), dopamine-depleting agent (tetrabenazine, reserpine), and GABA-ergic drugs (clonazepam, gabapentin).^{6,18} Over the past three decades, neuroleptics have become the main pharmacological therapy for HC-HB. Vidakovic et al. reported 19 of 25 patients with hemiballismus treated with haloperidol successfully showed improvement.¹⁹ Pimozide and benzodiazepines are also often used. According to recent research, agents that reduce dopamine have been reported to show much better benefits. Tetrabenazine, which reduces the production of presynaptic dopamine, norepinephrine, serotonin, and postsynaptic dopamine receptor antagonists has been shown to be more useful in the treatment of HC-HB secondary to stroke or non ketotic hyperglycemia.²⁰ Another benefit of tetrabenazine is a reduced risk of tardive dyskinesia compared to any typical and any atypical neuroleptics. Drug induced parkinsonism is the most common complication caused by the use of dopamine inhibiting agents or agents that reduce dopamine production.¹⁴

In the case of refractory HC-HB that is not responsive to treatment, stereotactic surgery and deep brain stimulation (DBS) can be very effective in controlling the movement of HC-HB. Contralateral (ventrolateral) thalamotomy and pallidotomy (posteroventral) have been successful.¹ Another option of surgery in rare cases is carotid endarterectomy for new onset HC-HB

and evidence of contralateral carotid stenosis (more than 70% is blocked).²¹

HC-HB is often temporary and can recover without the need of specific management. In an observational study of 15 patients with post-stroke HC-HB, 53% experienced fast resolution without treatment, and 73% experienced complete resolution of symptoms after 17 months.²² However, this case illustrates the need of early identification and adequate treatment when HC-HB does not spontaneously recover quickly and has a negative impact on the patient's safety and function. Haloperidol is often needed for the treatment of patients with HC-HB, although it is not enough to treat it perfectly. In this patient the functional improvement was shown after starting low-dose haloperidol, benzodiazepines, and well controlled of blood glucose level. Daily monitoring is required in this condition, so the patient was hospitalized and we stabilized the blood glucose level. We measured fasting glucose level and random glucose

Conflict of Interest

None

References

1. S Hawley JS, Weiner WJ. Hemiballismus: current concepts and review. *Journal Elsevier, Parkinsonism and Related Disorders*. 2012;18:125-9
2. Atay M, Yetia H, Kurtcan S, Aralasmak A, Alkan A. Susceptibility Weighted Imaging Features of Nonketotic Hyperglycemia: Unusual Cause of Hemichorea-Hemiballismus. *Journal Neuroimaging*. 2015;25:319-24
3. Gowtham M, Supriya C, Seetharambabu, Divya G. A case of hemiballismus due to uncontrolled diabetes. *J Acute Dis*. 2019;8:2:84-5.
4. Alkilani WZ, Tahir H, Gibb N, Ullah S, Vinod NR. Hyperglycemia Induced Reversible Hemiballismus as the Main Presentation of Newly Diagnosed Diabetes Mellitus *American Journal of Medical Case Reports*. 2016;4:7:245-7.
5. Jaafar J, Rahman RA, Draman N, Yunus NA. Hemiballismus in uncontrolled diabetes mellitus. *Korean J Fam Med*. 2018;39:3:200-3.
6. Mishra V, Jain S, Sorabjee J. Combination therapy in hemiballismus hemichorea syndromes-a report of two cases. *BJMS*. 2018;13:4:484-7.
7. GohLW, Chinchure D, Lim TC. Clinics in diagnostic imaging nonketotic hyperglycemia chorea-hemiballismus. *Singapore Med J*. 2016;57:3:161-4.
8. Hefter, H., P. Mayer, and R. Benecke. Persistent Chorea after Recurrent Hypoglycemia. *European Neurology Eur Neurol*. 2008;33:3:244-7
9. Demssie YN, Kaushal K. Newly diagnosed type-2 diabetes presenting with hemichorea-hemiballismus. *J R Coll Physicians Edinb*. 2008;38:218-20.
10. Mittal P. Hemichorea-hemiballismus syndrome: a look through susceptibility weighted imaging. *Ann Indian Acad Neurol*. 2011;14:2:124-6.
11. Bathla G, Policeni B, Agarwal A. Neuroimaging in patients with abnormal

- blood glucose levels. *AJNR Am J Neuroradiol.* 2013.
12. Arboix A, Lopez-Grau M, Casasnovas C, García-Eroles L, Massons J, Balcells M. Clinical study of 39 patients with atypical lacunar syndrome. *J Neurol Neurosurg Psychiatry.* 2006;77:3:381-4.
 13. Ohara S, Nakagawa S, Tabata K, et al. Hemiballism with hyperglycaemia and striatal T1-MR hyperintensity: an autopsy report. *Mov Disorders.* 2001;16:521-5.
 14. Postuma RB, Lang AE. Hemiballism: revisiting a classic disorder. *Lancet Neurol.* 2003;2:661-8.
 15. Oh SH, Lee KY, Im JH, Lee MS. Chorea associated with non-ketotic hyperglycemia and hyperintensity basal ganglia lesion on T1-weighted brain MRI study: a meta-analysis of 53 cases including four present cases. *J Neurol Sci.* 2002;200:57-62.
 16. Wilson TJ, Than KD, Stetler WR et al. Non-ketotic hyperglycemic chorea-hemiballismus mimicking basal ganglia hemorrhage. *J Clin Neurosci.* 2011;18:11:1560-1.
 17. Damani A, Ghoshal A, Salins N, Deodhar J, Muckaden MA. Management of Hemichorea Hemiballismus Syndrome in an Acute Palliative Care Setting. *Indian Journal of Palliative Care.* 2015;21:1:72-5.
 18. Ristic A, Marinkovic J, Dragasevic N, et al. Long-term prognosis of vascular hemiballismus. *Stroke.* 2002;33:2109-11.
 19. Vidakovic A, Dragasevic N, Kostic VS. Hemiballismus: report of 25 cases. *J Neurol Neurosurg Psychiatry.* 1884;57:945-9.
 20. Sitburana O, Ondo WG. Tetrabenazine for hyperglycemic-induced hemichorea-hemiballismus. *MovDisord.* 2006;21:2023-5.
 21. Galea I, Norwood F, Phillips MJ, Shearman C, McMonagle P, Gibb WR. Resolution of hemichorea following endarterectomy for severe carotid stenosis. *Neurology.* 2008;71:80-2.
 22. Pares I, Hernandez-Vara J, Alvarez-Sabin J. Post-stroke hemichorea: Observation-based study of 15 cases. *Rev Neurol.* 2010;51:460-4